

# Networks in Temporal Lobe Epilepsy



Karina A. González Otárula, MD<sup>a</sup>, Stephan Schuele, MD, MPH<sup>b,\*</sup>

## KEYWORDS

• Temporal lobe • Epilepsy • Connectivity • Networks

## KEY POINTS

- Epilepsy can be conceptualized as a disorder of neuronal networks.
- In this model, seizures and comorbidities associated with epilepsy are generated by a network of interdependent epileptogenic nodes rather than attributed to a single focus.
- The network can be analyzed according to the interaction or “connectivity” between its different parts using different methods.
- Neurophysiologic and imaging technologies have been used to evaluate functional and structural connectivity.
- Temporal lobe epilepsy is associated with a wide variety of network alterations. Understanding these network alterations may improve our ability to delineate the epileptogenic zone and predict seizure outcome.

## INTRODUCTION

The goal of resective epilepsy surgery is to remove the minimal area of cortex to produce seizure freedom, known as the epileptogenic zone (EZ).<sup>1</sup> Temporal lobe epilepsy (TLE) is the most common type of focal epilepsy and the most frequent target for resective epilepsy surgery. The International League Against Epilepsy classification of epilepsies from 1989 divided temporal lobe epilepsies in 2 main types: mesiotemporal (amygdalohippocampal) and lateral (neocortical) epilepsy.<sup>2</sup> However, with the experience from invasive electroencephalographic (EEG) recordings and surgical failure after surgery it has become more apparent that TLE can be considerably more complex, and involve various temporal as well as extratemporal lobe networks contributing to the extent of the EZ and directly affecting seizure outcome.<sup>3</sup>

Seizure onset in temporal lobe epilepsy can arise from interconnected structures within the temporal lobe or from the temporal lobe and neighboring regions more or less simultaneously.

Within the mesial temporal lobe, seizures can arise from the hippocampus alone or in association with the extrahippocampal medial temporal cortex.<sup>4</sup> The extent of hippocampus and entorhinal cortex resections are independently associated with seizure freedom, suggesting that in some patients the parahippocampal structures play an important role in seizure generation.<sup>5</sup> An improved chance of seizure freedom targeting entorhinal cortex and parahippocampal gyrus in addition to the hippocampus itself was also noted in a recent multicenter study using laser interstitial therapy.<sup>6</sup> Seizures with onset in both limbic structures and the neocortex were named medial-lateral subtype.<sup>7</sup> Aside from the mesial temporal structures, in this scenario seizures arise from the lateral cortex and the temporopolar cortex.<sup>8</sup> More complex seizure onset jointly arising from the temporal lobe and close neighboring structures have been named temporal plus seizures.<sup>9</sup> Temporal lobe plus seizures can implicate the orbitofrontal cortex, the operculum, the insula, and the temporo-parieto-occipital junction and are a major

<sup>a</sup> Department of Neurology, University of Iowa, University of Iowa Hospital and Clinics, 200 Hawkins Drive, Iowa City, IA 52242, USA; <sup>b</sup> Department of Neurology, Northwestern University, Feinberg School of Medicine, Neurological Testing Center, 251 East Huron Street, Galter Pavilion 7-104, Chicago, IL 60611, USA

\* Corresponding author.

E-mail address: [s-schuele@northwestern.edu](mailto:s-schuele@northwestern.edu)

contributor for surgical failure after anterior temporal resections.<sup>10,11</sup> Finally, seizures that arise from outside the temporal lobe, but whose semiology or electro clinical features mimic those of TLE, are named pseudotemporal lobe seizures.

Based on the spatiotemporal organization of the epileptic brain tissue and the consequent alterations in the remaining structures, focal epilepsy is proposed to be a disorder of neuronal networks.<sup>12</sup> The network concept states the obvious that seizures and other comorbidities of epilepsy cannot be explained by a spatially restricted abnormality of the brain and introduces the idea of epilepsy affecting the whole brain to various degrees. The concept of a network is able to explain factors beyond a focal abnormality that affect surgical outcome in TLE, such as duration of epilepsy, early seizure spread, or presence of bilateral convulsive seizures. Even if the goal of epilepsy surgery remains to remove the minimal amount of cortex to render a patient seizure free, it is helpful to consider the area to be resected as a “critical node” of the epileptic network.

Human brain networks can be evaluated from different perspectives. The area initiating an epileptic seizure can be considered a micro network allowing the study of seizure initiation.<sup>13</sup> The EZ can be conceptualized as a network distinct from the area of propagation and clinical seizure expression.<sup>3</sup> Based on the extent of brain critical for seizure generation, epileptic seizures have been divided into regional, lobar, hemispheric, and bilateral networks.<sup>14,15</sup> Electrical cortical stimulation and resection studies have expanded our view of eloquent and silent cortex, allowing us to consider human brain function as a network with “essential” nodes and other more dispensable regions.<sup>16</sup>

Networks can be analyzed according to the interactions or “connectivity” between their different parts using a variety of methods. These interactions could be structural (“structural connectivity”) or functional. Among the functional interactions, it is possible to analyze the nondirectional statistical dependency between different signals (“functional connectivity”) or the directional/causal interactions (“effective connectivity”).<sup>17</sup> (Fig. 1) Structural connectivity networks in epilepsy allow the study of widespread alterations in gray matter morphology and white matter connections associated with various epilepsy syndromes. Graph theory is 1 method that allows studying the topologic properties of the functional or structural network as an organization made out of “nodes” with its links to other parts named “edges.”<sup>18</sup> To further characterize networks, specific nodes can be viewed as “hubs” crucial for efficient

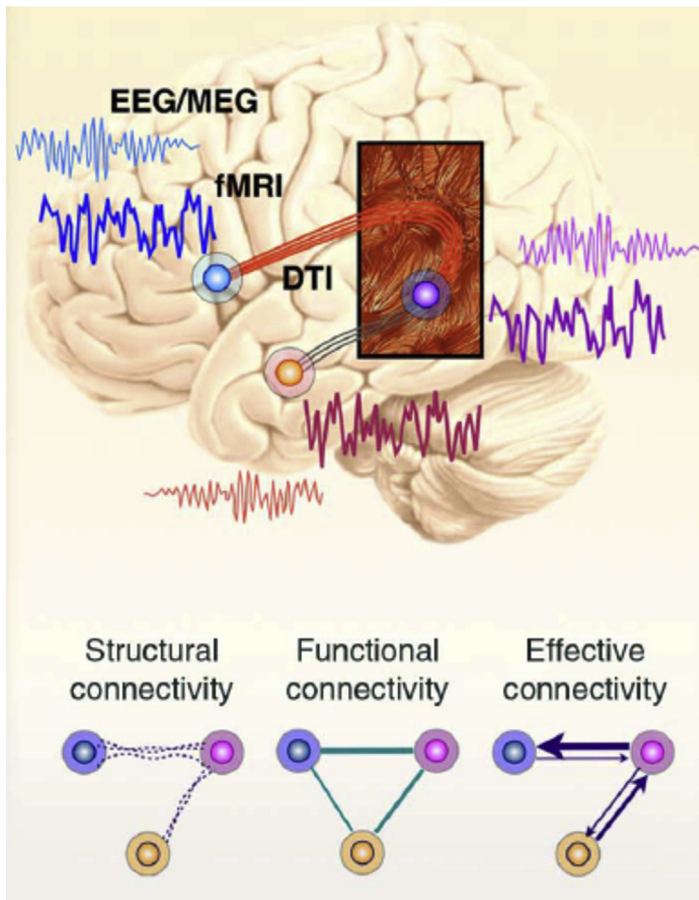
communication, with pathologic hubs seen in the epileptogenic areas.<sup>19</sup> In TLE, this network concept has been studied using neurophysiological methods and neuroimaging, as we review below.

## NEUROPHYSIOLOGIC NETWORKS

### *Interictal Networks*

Brain networks in TLE can be analyzed at the time of the interictal spikes or during the nonspiking “resting state” interictal period. It is hypothesized that coactivated regions during interictal spikes may facilitate strong connections among the regions involved, resulting in an epileptic network. A study in mesial TLE using stereoencephalography (SEEG) showed that there are reproducible subsets of temporal lobe brain structures that are jointly involved in the generation of interictal spikes.<sup>20</sup> These brain networks involved mainly the mesial temporal lobe structures, but in half of the patients independent neocortical networks were also observed. This study showed that the networks involved during interictal spikes vary among different patients but tend to be consistent within 1 patient. This consistency of interictal spike propagation was also shown to be reproducible in other types of epilepsy.<sup>21</sup> A more recent study investigated the strength and direction of the networks based on interictal spikes in 10 patients with mesial TLE. It showed that the most prevalent connection was from the hippocampus to the amygdala, followed by propagation between the parahippocampal gyrus and amygdala on the left side and between the anterior fusiform gyrus and amygdala on the right side.<sup>22</sup> A study including mesial and nonmesial patients with TLE who underwent intraoperative electrocorticography found clusters of synchronized activity at specific areas of the lateral temporal cortex that, when resected, correlated with good seizure outcome.<sup>23</sup> This again showed that areas of higher interdependence might be involved in seizure generation. Similar to epileptiform spikes, interictal high frequency oscillations, considered to be a better marker of epileptogenicity, have been proposed to have propagation phenomena and network organization.<sup>24–26</sup>

Analysis of the interictal intracranial EEG, not limited to interictal epileptiform discharges, also showed local increase in the interictal synchrony in structures within the EZ in TLE. Even when spikes are suppressed from the analyzed interictal EEG periods, functional coupling in the mesial temporal structures is increased.<sup>27</sup> A study with resting-state SEEG data free of interictal spikes that included 12 patients with mesial TLE and 3



**Fig. 1.** Schematic representation of brain networks. Brain network connections or “edges” can be defined by 3 types of connectivity: structural, functional, and effective. Structural connectivity refers to anatomic connections and is frequently estimated by fiber tractography from diffusion tensor MRI (DTI). These connections are illustrated with broken lines in the bottom images. Functional and effective connectivity are generally inferred from the activity of remote nodes as measured by using BOLD-fMRI or EEG/MEG signals. Functional connectivity does not provide directionality or causality and is therefore depicted without arrows. Effective connectivity can evaluate directionality. This is illustrated by the 1-sided arrows. (From Park HJ, Friston K. Structural and functional brain networks: from connections to cognition. *Science* 2013;342:1238411; with permission.)

with neocortical epilepsy showed increased functional connectivity within the epileptogenic regions and between epileptogenic areas and other structures.<sup>28</sup> A recent study using intracranial EEG showed that the interictal epileptiform discharges, particularly those occurring in the temporal lobe, could induce coupled spindles outside the ictal network, suggesting a global interictal network dysfunction.<sup>29</sup>

Although intracranial EEG recording have a high temporal resolution and can record from deep structures, they are restricted by limited spatial sampling and absent coverage of areas not hypothesized to be involved in seizure generation and propagation. Noninvasive neurophysiological techniques, such as high-density EEG and magnetoencephalography (MEG) have been used to assess large-scale brain connectivity. It is known that epileptic activity affects brain regions beyond the epileptogenic region. A study using high-density EEG showed an asymmetry on the connectivity patterns in right and left TLE, demonstrating more ipsilateral to contralateral spike-

related connectivity in right TLE than in left TLE.<sup>30</sup> MEG recordings have been used to map the propagation of temporal lobe spikes, which correlated well with invasive EEG propagation.<sup>31</sup> A study applying resting-state MEG looking at 44 patients, 22 with right and 22 with left hippocampal sclerosis, showed altered functional hubs in patients with left hippocampal sclerosis compared with controls but not in patients with right hippocampal sclerosis, which the authors attributed to intrinsic functional and structural asymmetries between patients with right and left TLE.<sup>32</sup> Functional hubs localized to the EZ in patients with good surgical outcome but not in patients failing surgery.<sup>33</sup>

### ***Ictal Networks***

The pioneers of SEEG, Bancaud and Talairach, proposed the idea that the epileptogenic “lesion” or zone can be defined preoperatively through a detailed understanding of the brain network involved in the primary organization of the seizure.<sup>34</sup> Different structures could be coinvolved

at the seizure onset in patients with TLE, including mesial, lateral, mesial-lateral, and temporal-perisylvian structures.<sup>35</sup> In mesial TLE, 2 main seizure onset patterns have been described: hypersynchronous activity seen when the onset involves mainly the mesial temporal structures and low-voltage fast activity onset involving mesial and lateral temporal, as well as the orbitofrontal cortex.<sup>36</sup> Hypersynchronous, repetitive spiking is associated with better outcome after surgery, likely related to its high specificity for mesial temporal sclerosis.<sup>37</sup> In many instances, low voltage fast (LVF) involves several brain regions rapidly at seizure onset. Quantification of LVF over individual electrodes allows creating the so-called epileptogenicity index representing the spectral power of LVF activity over time in 3-dimensional space as a representation of the epileptogenic network.<sup>3</sup> A recent study in 17 seizure-free patients after SEEG evaluation and resection applied Morlet wavelet transformation to create time-frequency plots of fast- and low-frequency activity.<sup>38</sup> The combination of spikes preceding multiband fast activity and loss of low frequencies in the seizure onset zone generated a characteristic pattern, which was recognizable in 15 out of 17 patients through a machine-learning algorithm, with 58 out of 64 contacts localized within the resection area.

Coherence analysis during invasive recordings using SEEG has not only been used to describe subtypes of temporal lobe epilepsies, it also demonstrates that neuronal networks show a more ordered configuration during a seizure compared with the interictal state.<sup>3</sup> Preictal synchronization can be seen in patients with mesial TLE involving the hippocampus and entorhinal cortex. Increased thalamocortical synchronization using SEEG involving the thalamus has been observed during seizure termination and negatively correlated with seizure duration. Excessive synchronization can be seen in structures associated with specific ictal semiologies, including humming or loss of awareness. In 8 patients undergoing temporal lobe surgery, effective connectivity measures showed that, during the first 20 seconds of ictal EEG, electrodes with the highest outgoing connectivity corresponded well with the seizure onset zone.<sup>39</sup> In a study that used scalp EEG and foramen ovale recordings, it was possible to identify seizures that were not visually identified by looking only at scalp EEG recording using scalp EEG-based coherence measures.<sup>40</sup>

Cortical electrical stimulation is a tool used during depth electrode evaluations not only to assist with functional mapping but also to further define the epileptogenic network by eliciting the patient's

habitual symptoms and EEG seizure pattern, identifying electrodes essential for seizure generation with a similar accuracy as spontaneously captured seizures.<sup>41</sup> Single-pulse electrical stimulation to elicit corticocortical evoked responses has been predominantly used to understand functional connections of the brain.<sup>42</sup> Further studies suggested that seizure onset areas were associated with an increased N1 response compared with normal brain, correlating with a particular seizure pattern of repetitive spiking before LVF activity linked with improved outcome.

It is well known that rapid contralateral propagation of temporal lobe seizures predicts poor surgical outcome.<sup>43</sup> In patients with mesial TLE who underwent invasive explorations it was demonstrated that patients with rapid seizure spread outside the mesial structures were significantly more likely to have recurrent seizures after anterior medial temporal resection.<sup>44</sup> Another study including 39 seizures with mesial temporal lobe onset, comparing seizures that remained focal versus those that generalized, demonstrated that in seizures with secondary generalization the seizure activity consistently involved the posterior-lateral temporal region before propagation to other regions.<sup>45</sup> The authors suggested an epileptogenic potential of structures that are involved in early seizure propagation. Seizure propagation patterns have certainly an important impact when estimating prognosis after surgery. However, it remains to be seen if more extensive resections for temporal plus epilepsies or additional targeted resection or stimulation of propagation nodes would positively affect seizure-free outcome and outweigh the additional risk.

## IMAGING NETWORKS

### *Structural Networks*

Advances in neuroimaging have allowed studying epilepsy pathologic structural substrates and networks noninvasively. The term structural connectivity refers to anatomic interactions between brain regions. Quantitative neuroimaging has widened the understanding of the structural pathology in TLE. Very detailed analysis of the temporal lobe architecture can be performed with high-resolution MRI. In mesial TLE volumetric analysis of the hippocampus, T1 and T2 intensity changes are used for presurgical diagnosis of hippocampal sclerosis and have been correlated with findings of pathological conditions.<sup>46</sup> Beyond the focal pathology, more diffuse alterations in the gray matter have been found in TLE. MRI-based morphologic metrics, such as gray matter volume and cortical thickness, allow for better study of the

architecture of the gray matter. A recent study using quantitative analysis showed intracortical anomalies in the mesiotemporal and paralimbic areas suggesting coupled structural alterations.<sup>47</sup> A morphometric MRI study in mesial TLE showed increased covariance within the hippocampus, entorhinal cortex, and amygdala, hypothesized by the authors to be related to axonal sprouting. The authors also noted a decreased interstructure covariance suggesting a disconnection within the limbic circuit.<sup>48</sup> Cortical thickness and gray matter morphology analysis have shown a more widespread alteration with an association between TLE and bilateral neocortical atrophy that affects lateral temporal, frontocentral, parietal regions, and the thalamus.<sup>18</sup>

Diffusion-weighted MRI tractography provides information on structural connectivity by visualizing the architecture of the white matter. Clinically, diffusion tractography has been used to guide probe placement during interstitial laser ablation of the mesial temporal lobe to avoid damage to the visual pathways.<sup>49</sup> Diffusion MRI studies in TLE have shown decreased fractional anisotropy, particularly in the ipsilateral temporo- limbic tracts affecting the fornix, parahippocampal fibers, uncinate fasciculus, and cingulum,<sup>50</sup> showing a higher correlation with the presence of a structural hippocampal abnormality and less widespread changes than morphometric MRI connectivity studies (Fig. 2 shows examples of studies on structural and functional networks in TLE).

### **Functional Networks**

Functional networks in TLE using imaging technology have been investigated with different approaches, including PET, functional MRI (fMRI), and single-photon emission computed tomography (SPECT). These functional networks have been investigated during the interictal period (resting state and at the time of interictal spikes: spike-related) and during the ictal period.

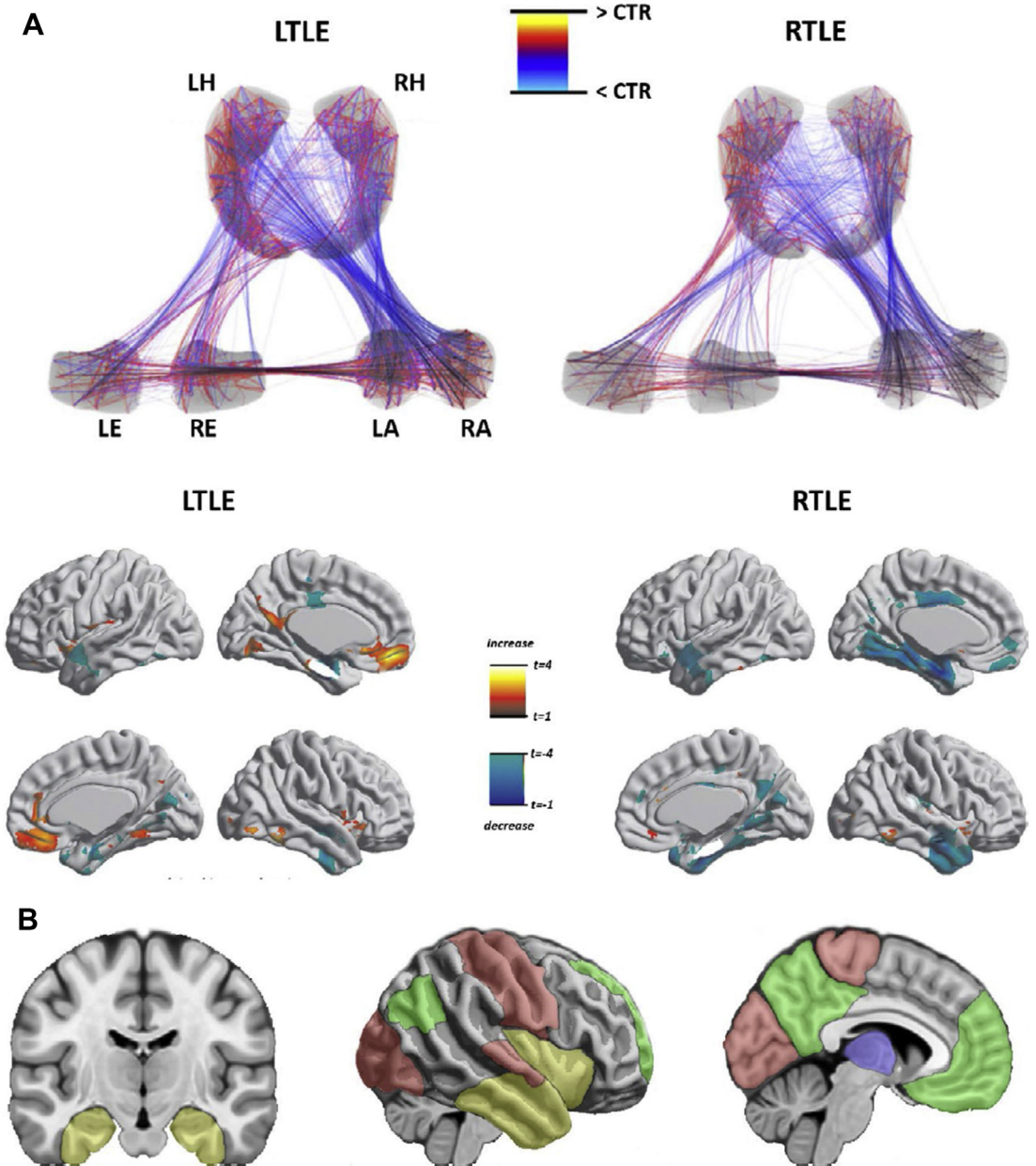
Fluorodeoxyglucose (FDG)-PET scans in TLE can help with the identification of the EZ demonstrating hypometabolism.<sup>51</sup> Ipsilateral temporal hypometabolism to the seizure onset has been associated with good surgical outcome, and hypometabolism beyond the seizure onset zone or bilaterally has been associated with less favorable outcome. FDG-PET data can be used to analyze the metabolic brain connectivity. In TLE, a study that used graph theory-based analysis showed altered and asymmetric connectivity in right and left TLE. Higher lobar connectivity was found in right TLE compared with left TLE for connections of the temporal and the parietal lobes of the

contralateral hemisphere, which the authors suggest could be attributed to compensatory effects.<sup>52</sup>

Most of the studies involving fMRI have used task-free resting state, based on spontaneous fluctuations in the blood oxygenation level-dependent (BOLD) signals, investigating the relation between different brain regions during this interictal period. TLE studies also have shown impaired connectivity of the mesiotemporal structures, for example, between the anterior and posterior hippocampus and the hippocampus and entorhinal cortex,<sup>53</sup> in contrast to the EEG-based functional connectivity studies, which demonstrated increased connectivity in the epileptogenic areas.<sup>28</sup> Altered functional connectivity has also been found between mesial structures and other structures, such as temporal neocortex and subcortical structures, such as the thalamus.<sup>54–56</sup> When assessing the default mode networks, which consist of the deactivation of specific regions during the performance of cognitive tasks and activation during resting with eyes closed, a study showed alterations in the default mode networks in patients with mesial TLE.<sup>57</sup> The changes in default mode functional connectivity in TLE seem to be directly related to the severity of the hippocampal atrophy.<sup>58</sup> Functional connectivity patterns in patients who successfully underwent temporal lobe surgery have been used to predict surgical outcome.<sup>59</sup>

A combined strategy that includes a neurophysiological approach and functional imaging is EEG-fMRI. This approach allows studying the hemodynamic changes that are related to interictal epileptiform activity seen in EEG. In TLE, EEG-fMRI studies have shown extensive hemodynamic changes during unilateral temporal lobe spikes, including ipsilateral mesial temporal structures, basal ganglia, and bilateral neocortical temporal regions.<sup>60</sup> Interestingly, interictal epileptiform discharges adjacent to the maximum BOLD response have a high correlation with the seizure onset zone during subsequent SEEG recordings, suggesting that EEG-fMRI response can reveal the origin of interictal epileptiform discharges or “spike onset zone.”<sup>61</sup>

Ictal SPECT allows assessing the cerebral perfusion during a seizure. Cerebral blood flow and brain metabolism markedly increase during seizure initiation and propagation. In mesial TLE ictal SPECT shows hyperperfusion in the medial temporal region as well as in the insula, putamen, thalamus, and cerebellum.<sup>62</sup> Resection of at least part of the most prominent hyperperfusion signal has been associated with good surgical outcome.<sup>63</sup>



**Fig. 2.** Examples of structural and functional network abnormalities in TLE. (A) Upper panel shows results of structural covariance of mesiotemporal subnetworks between patients with left TLE, right TLE, and controls (CTR). Increases/decreases in patients relative to controls are shown in red/blue. This demonstrates reconfigurations of mesiotemporal connectivity. Lower panel shows abnormalities of structural connectivity of the ipsilateral entorhinal cortex in left and right TLE compared with controls. (B) Summary of studies reporting functional connectivity alterations in TLE. Corticosubcortical altered regions belong to temporolimbic, default mode, sensory-motor, and thalamocortical networks. LA/RA, left/right amygdala; LE/RE, left/right entorhinal cortex; LH/RH, left/right hippocampus. ([A] Adapted from Bernhardt BC, Bernasconi N, Hong SJ, et al. Subregional mesiotemporal network topology is altered in temporal lobe epilepsy. *Cereb Cortex* 2016;26:3242; and Bernhardt BC, Worsley KJ, Besson P, et al. Mapping limbic network organization in temporal lobe epilepsy using morphometric correlations: insights on the relation between mesiotemporal connectivity and cortical atrophy. *Neuroimage* 2008;42:519; with permission. [B] Adapted from Caciagli L, Bernhardt BC, Hong SJ, et al. Functional network alterations and their structural substrate in drug-resistant epilepsy. *Front Neurosci* 2014;8:411; with permission.)

## NEUROPSYCHIATRIC COMORBIDITIES

Neuropsychological dysfunctions are a common comorbidity in patients with TLE indicating that epilepsy as a network disease can disturb complex functions involving different cognitive domains. These dysfunctions are seen in TLE independently of whether a macroscopic lesion is present.<sup>64</sup> Epilepsy duration plays a role in cognitive disturbance, which often worsen over time. Task-related functional connectivity was studied in patients with TLE showing that language networks are altered in patients with seizures starting earlier in life and with prolonged disease duration.<sup>65</sup> White matter changes can be used to identify patients with language impairment in TLE.<sup>66</sup> Three cognitive phenotypes have been proposed in TLE: minimally impaired, memory impaired, and memory, executive, and speed impaired. The most impaired group was associated with longer epilepsy duration and more abnormal brain volume among other characteristics.<sup>67</sup> Improvement in some aspects of cognition has also been reported after TLE surgery.<sup>68</sup> The absence of the resected dysfunctional cortex and network adaptations in response to seizure freedom have been proposed as an explanation. It was shown that hyperconnectivity of distributed areas supports the episodic memory function in patients with resected mesial temporal structures.<sup>69</sup>

The limbic system is associated with the control of emotions, and depression and anxiety are a common comorbidity in TLE.<sup>70</sup> In patients with mesial TLE, depression is associated with relative preservation of the contralateral amygdala on imaging.<sup>71</sup> Frontolimbic network dysfunction has been proposed to be a strong contributor to the presence of depressive symptoms.<sup>72,73</sup> MRI-negative TLE was associated with a similar degree of not only memory dysfunction but also mood disorders, as seen in patients with hippocampal sclerosis or other MRI lesions.<sup>64</sup> Resting-state fMRI studies show a similar pattern of functional connectivity changes involving the default mode network, dorsal attention, and the reward-emotion network in epilepsy and depression.

## SUMMARY

TLE can be conceptualized as a network disorder, which allows a better understanding of seizure initiation, propagation, outcome, and comorbidities. A variety of methods are available to evaluate time-related functional networks and the time-independent structural connectivity of the human brain. Abnormalities in brain connectivity found with noninvasive imaging methods are not

necessarily associated with an obvious structural lesion on conventional imaging and may help to localize the EZ in the absence of a lesion.

## DISCLOSURE

The authors have nothing to disclose.

## REFERENCES

1. Luders HO, Najm I, Nair D, et al. The epileptogenic zone: general principles. *Epileptic Disord* 2006; 8(Suppl 2):S1–9.
2. Proposal for revised classification of epilepsies and epileptic syndromes. Commission on Classification and Terminology of the International League against Epilepsy. *Epilepsia* 1989;30:389–99.
3. Bartolomei F, Lagarde S, Wendling F, et al. Defining epileptogenic networks: contribution of SEEG and signal analysis. *Epilepsia* 2017;58:1131–47.
4. Bonilha L, Martz GU, Glazier SS, et al. Subtypes of medial temporal lobe epilepsy: influence on temporal lobectomy outcomes? *Epilepsia* 2012;53:1–6.
5. Bonilha L, Yasuda CL, Rorden C, et al. Does resection of the medial temporal lobe improve the outcome of temporal lobe epilepsy surgery? *Epilepsia* 2007;48:571–8.
6. Wu C, Jermakowicz WJ, Chakravorti S, et al. Effects of surgical targeting in laser interstitial thermal therapy for mesial temporal lobe epilepsy: a multicenter study of 234 patients. *Epilepsia* 2019;60:1171–83.
7. Maillard L, Vignal JP, Gavaret M, et al. Semiology and electrophysiologic correlations in temporal lobe seizure subtypes. *Epilepsia* 2004;45:1590–9.
8. Chabardes S, Kahane P, Minotti L, et al. The temporopolar cortex plays a pivotal role in temporal lobe seizures. *Brain* 2005;128:1818–31.
9. Kahane P, Barba C, Rheims S, et al. The concept of temporal 'plus' epilepsy. *Rev Neurol (Paris)* 2015; 171:267–72.
10. Barba C, Barbati G, Minotti L, et al. Ictal clinical and scalp-EEG findings differentiating temporal lobe epilepsies from temporal 'plus' epilepsies. *Brain* 2007; 130:1957–67.
11. Barba C, Rheims S, Minotti L, et al. Temporal plus epilepsy is a major determinant of temporal lobe surgery failures. *Brain* 2016;139:444–51.
12. Spencer SS. Neural networks in human epilepsy: evidence of and implications for treatment. *Epilepsia* 2002;43:219–27.
13. Schevon CA, Tobochnik S, Eissa T, et al. Multiscale recordings reveal the dynamic spatial structure of human seizures. *Neurobiol Dis* 2019;127:303–11.
14. Berg AT, Berkovic SF, Brodie MJ, et al. Revised terminology and concepts for organization of seizures and epilepsies: report of the ILAE Commission on

- Classification and Terminology, 2005–2009. *Epilepsia* 2010;51:676–85.
15. Luders H, Vaca GF, Akamatsu N, et al. Classification of paroxysmal events and the four-dimensional epilepsy classification system. *Epileptic Disord* 2019; 21:1–29.
  16. Schuele SU, Mcintyre C, Lüders HO. General Principles of Cortical Mapping by Electrical Stimulation. In: Lüders HO, editor. *Textbook of epilepsy surgery*. London: Informa; 2008. p. 963–77.
  17. Yaffe RB, Borger P, Megevand P, et al. Physiology of functional and effective networks in epilepsy. *Clin Neurophysiol* 2015;126:227–36.
  18. Tavakol S, Royer J, Lowe AJ, et al. Neuroimaging and connectomics of drug-resistant epilepsy at multiple scales: from focal lesions to macroscale networks. *Epilepsia* 2019;60:593–604.
  19. van Diessen E, Diederer SJ, Braun KP, et al. Functional and structural brain networks in epilepsy: what have we learned? *Epilepsia* 2013;54:1855–65.
  20. Bourien J, Bartolomei F, Bellanger JJ, et al. A method to identify reproducible subsets of co-activated structures during interictal spikes. Application to intracerebral EEG in temporal lobe epilepsy. *Clin Neurophysiol* 2005;116:443–55.
  21. Tomlinson SB, Wong JN, Conrad EC, et al. Reproducibility of interictal spike propagation in children with refractory epilepsy. *Epilepsia* 2019;60:898–910.
  22. Karunakaran S, Rollo MJ, Kim K, et al. The interictal mesial temporal lobe epilepsy network. *Epilepsia* 2018;59:244–58.
  23. Ortega GJ, Menendez de la Prida L, Sola RG, et al. Synchronization clusters of interictal activity in the lateral temporal cortex of epileptic patients: intraoperative electrocorticographic analysis. *Epilepsia* 2008;49:269–80.
  24. Tamilia E, Park EH, Percivati S, et al. Surgical resection of ripple onset predicts outcome in pediatric epilepsy. *Ann Neurol* 2018;84:331–46.
  25. Gonzalez Otárola KA, von Ellenrieder N, Cuello Oderiz C, et al. High-frequency oscillation networks and surgical outcome in adult focal epilepsy. *Ann Neurol* 2019;85:485–94.
  26. Fink CG, Gliske S, Catoni N, et al. Network mechanisms generating abnormal and normal hippocampal high-frequency oscillations: a computational analysis. *eNeuro* 2015;2.
  27. Bettus G, Wendling F, Guye M, et al. Enhanced EEG functional connectivity in mesial temporal lobe epilepsy. *Epilepsy Res* 2008;81:58–68.
  28. Goodale SE, Gonzalez HFJ, Johnson GW, et al. Resting-state SEEG may help localize epileptogenic brain regions. *Neurosurgery* 2019. <https://doi.org/10.1093/neuros/hyz351>.
  29. Dahal P, Ghani N, Flinker A, et al. Interictal epileptiform discharges shape large-scale intercortical communication. *Brain* 2019;142:3502–13.
  30. Coito A, Plomp G, Genetti M, et al. Dynamic directed interictal connectivity in left and right temporal lobe epilepsy. *Epilepsia* 2015;56:207–17.
  31. Tanaka N, Hamalainen MS, Ahlfors SP, et al. Propagation of epileptic spikes reconstructed from spatiotemporal magnetoencephalographic and electroencephalographic source analysis. *Neuroimage* 2010;50:217–22.
  32. Jin SH, Jeong W, Chung CK. Mesial temporal lobe epilepsy with hippocampal sclerosis is a network disorder with altered cortical hubs. *Epilepsia* 2015; 56:772–9.
  33. Nissen IA, Stam CJ, Reijneveld JC, et al. Identifying the epileptogenic zone in interictal resting-state MEG source-space networks. *Epilepsia* 2017;58: 137–48.
  34. Bancaud J, Talairach J. *La stereo-electroencephalographie dans l'épilepsie: informations neurophysiopathologiques apportées par l'investigation fonctionnelle stéréotaxique*. Paris: Masson; 1965.
  35. Bartolomei F, Cosandier-Rimele D, McGonigal A, et al. From mesial temporal lobe to temporoparietal seizures: a quantified study of temporal lobe seizure networks. *Epilepsia* 2010;51:2147–58.
  36. Memarian N, Madsen SK, Macey PM, et al. Ictal depth EEG and MRI structural evidence for two different epileptogenic networks in mesial temporal lobe epilepsy. *PLoS One* 2015;10:e0123588.
  37. Perucca P, Dubeau F, Gotman J. Intracranial electroencephalographic seizure-onset patterns: effect of underlying pathology. *Brain* 2014;137:183–96.
  38. Grinenko O, Li J, Mosher JC, et al. A fingerprint of the epileptogenic zone in human epilepsies. *Brain* 2018;141:117–31.
  39. van Mierlo P, Carrette E, Hallez H, et al. Ictal-onset localization through connectivity analysis of intracranial EEG signals in patients with refractory epilepsy. *Epilepsia* 2013;54:1409–18.
  40. Lam AD, Zepeda R, Cole AJ, et al. Widespread changes in network activity allow non-invasive detection of mesial temporal lobe seizures. *Brain* 2016;139:2679–93.
  41. Cuello Oderiz C, von Ellenrieder N, Dubeau F, et al. Association of cortical stimulation-induced seizure with surgical outcome in patients with focal drug-resistant epilepsy. *JAMA Neurol* 2019. <https://doi.org/10.1001/jamaneurol.2019.1464>.
  42. Matsumoto R, Kunieda T, Nair D. Single pulse electrical stimulation to probe functional and pathological connectivity in epilepsy. *Seizure* 2017;44:27–36.
  43. Schulz R, Luders HO, Hoppe M, et al. Interictal EEG and ictal scalp EEG propagation are highly predictive of surgical outcome in mesial temporal lobe epilepsy. *Epilepsia* 2000;41:564–70.
  44. Andrews JP, Gummadavelli A, Farooque P, et al. Association of seizure spread with surgical failure in epilepsy. *JAMA Neurol* 2019;76:462–9.



45. Yoo JY, Farooque P, Chen WC, et al. Ictal spread of medial temporal lobe seizures with and without secondary generalization: an intracranial electroencephalography analysis. *Epilepsia* 2014;55:289–95.
46. Goubran M, Bernhardt BC, Cantor-Rivera D, et al. In vivo MRI signatures of hippocampal subfield pathology in intractable epilepsy. *Hum Brain Mapp* 2016;37:1103–19.
47. Bernhardt BC, Fadaie F, Vos de Wael R, et al. Preferential susceptibility of limbic cortices to microstructural damage in temporal lobe epilepsy: a quantitative T1 mapping study. *Neuroimage* 2018;182:294–303.
48. Bernhardt BC, Bernasconi N, Hong SJ, et al. Subregional mesiotemporal network topology is altered in temporal lobe epilepsy. *Cereb Cortex* 2016;26:3237–48.
49. Voets NL, Alvarez I, Qiu D, et al. Mechanisms and risk factors contributing to visual field deficits following stereotactic laser amygdalohippocampotomy. *Stereotact Funct Neurosurg* 2019;97:255–65.
50. Bernhardt BC, Hong S, Bernasconi A, et al. Imaging structural and functional brain networks in temporal lobe epilepsy. *Front Hum Neurosci* 2013;7:624.
51. Chassoux F, Artiges E, Semah F, et al. 18F-FDG-PET patterns of surgical success and failure in mesial temporal lobe epilepsy. *Neurology* 2017;88:1045–53.
52. Vanicek T, Hahn A, Traub-Weidinger T, et al. Insights into intrinsic brain networks based on graph theory and PET in right- compared to left-sided temporal lobe epilepsy. *Sci Rep* 2016;6:28513.
53. Bettus G, Guedj E, Joyeux F, et al. Decreased basal fMRI functional connectivity in epileptogenic networks and contralateral compensatory mechanisms. *Hum Brain Mapp* 2009;30:1580–91.
54. Maccotta L, He BJ, Snyder AZ, et al. Impaired and facilitated functional networks in temporal lobe epilepsy. *Neuroimage Clin* 2013;2:862–72.
55. Haneef Z, Lenartowicz A, Yeh HJ, et al. Functional connectivity of hippocampal networks in temporal lobe epilepsy. *Epilepsia* 2014;55:137–45.
56. He X, Doucet GE, Sperling M, et al. Reduced thalamocortical functional connectivity in temporal lobe epilepsy. *Epilepsia* 2015;56:1571–9.
57. Zanao TA, Lopes TM, de Campos BM, et al. Patterns of default mode network in temporal lobe epilepsy with and without hippocampal sclerosis. *Epilepsy Behav* 2019. <https://doi.org/10.1016/j.yepbeh.2019.106523>.
58. Bernhardt BC, Bernasconi A, Liu M, et al. The spectrum of structural and functional imaging abnormalities in temporal lobe epilepsy. *Ann Neurol* 2016;80:142–53.
59. Morgan VL, Englot DJ, Rogers BP, et al. Magnetic resonance imaging connectivity for the prediction of seizure outcome in temporal lobe epilepsy. *Epilepsia* 2017;58:1251–60.
60. Kobayashi E, Grova C, Tyvaert L, et al. Structures involved at the time of temporal lobe spikes revealed by interindividual group analysis of EEG/fMRI data. *Epilepsia* 2009;50:2549–56.
61. Khoo HM, von Ellenrieder N, Zazubovits N, et al. The spike onset zone: the region where epileptic spikes start and from where they propagate. *Neurology* 2018;91:e666–74.
62. Sequeira KM, Tabesh A, Sainju RK, et al. Perfusion network shift during seizures in medial temporal lobe epilepsy. *PLoS One* 2013;8:e53204.
63. Jalota A, Rossi MA, Pylypyuk V, et al. Resecting critical nodes from an epileptogenic circuit in refractory focal-onset epilepsy patients using subtraction ictal SPECT coregistered to MRI. *J Neurosurg* 2016;125:1565–76.
64. Rayner G, Tailby C, Jackson G, et al. Looking beyond lesions for causes of neuropsychological impairment in epilepsy. *Neurology* 2019;92:e680–9.
65. Trimmel K, van Graan AL, Caciagli L, et al. Left temporal lobe language network connectivity in temporal lobe epilepsy. *Brain* 2018;141:2406–18.
66. Kaestner E, Balachandra AR, Bahrami N, et al. The white matter connectome as an individualized biomarker of language impairment in temporal lobe epilepsy. *Neuroimage Clin* 2019;25:102125.
67. Hermann B, Seidenberg M, Lee EJ, et al. Cognitive phenotypes in temporal lobe epilepsy. *J Int Neuropsychol Soc* 2007;13:12–20.
68. Shin MS, Lee S, Seol SH, et al. Changes in neuropsychological functioning following temporal lobectomy in patients with temporal lobe epilepsy. *Neurol Res* 2009;31:692–701.
69. Jeong W, Lee H, Kim JS, et al. Characterization of brain network supporting episodic memory in the absence of one medial temporal lobe. *Hum Brain Mapp* 2019;40:2188–99.
70. Spencer DD, Gerrard JL, Zaveri HP. The roles of surgery and technology in understanding focal epilepsy and its comorbidities. *Lancet Neurol* 2018;17:373–82.
71. Briellmann RS, Hopwood MJ, Jackson GD. Major depression in temporal lobe epilepsy with hippocampal sclerosis: clinical and imaging correlates. *J Neurol Neurosurg Psychiatry* 2007;78:1226–30.
72. Kemmotsu N, Kucukboyaci NE, Leyden KM, et al. Frontolimbic brain networks predict depressive symptoms in temporal lobe epilepsy. *Epilepsy Res* 2014;108:1554–63.
73. Wykes RC, Khoo HM, Caciagli L, et al. WONOEP appraisal: network concept from an imaging perspective. *Epilepsia* 2019;60:1293–305.